

# Methods of cryopreservation of testicular tissue with viable spermatogonia in pre-pubertal boys undergoing gonadotoxic cancer treatment

Victoria Keros<sup>1,5</sup>, Kjell Hultenby<sup>2</sup>, Birgit Borgström<sup>3</sup>, Margareta Fridström<sup>1</sup>, Kirsi Jahnukainen<sup>4</sup> and Outi Hovatta<sup>1</sup>

<sup>1</sup>Karolinska Institute, Division of Obstetrics and Gynaecology, Department of Clinical Science, Technology and Intervention, <sup>2</sup>Clinical Research Centre, <sup>3</sup>Department of Paediatrics, Karolinska University Hospital, Huddinge, SE 141 86 Stockholm, Sweden and <sup>4</sup>Paediatric Endocrinology Unit, Astrid Lindgren Children's Hospital, Karolinska Institute, Stockholm, Sweden

<sup>5</sup>To whom correspondence should be addressed at: Karolinska University Hospital—Huddinge, Department of Obstetrics and Gynaecology, K57, SE 141 86 Stockholm, Sweden. Tel.: +46-8-5858-3636; Fax: +46-8-5858-7575; E-mail: Victoria.Keros@ki.se

**BACKGROUND:** Banking of testicular tissue from pre-pubertal boys before gonadotoxic treatment is a crucial step in fertility preservation. We wanted to find optimal methods for cryopreservation of testicular tissue from pre-pubertal boys, modifying techniques developed for fetal and adult human testicular tissue cryopreservation. **METHODS:** Testicular tissue was collected from five pre-pubertal boys undergoing gonadotoxic treatment in a clinical programme. Two freezing protocols, originally developed for fetal and adult human testicular tissue, were applied for pre-pubertal testicular tissue cryopreservation. In both methods, 5% dimethyl sulphoxide (DMSO) was used as a cryoprotectant. The integrity of the tissue was investigated in non-frozen tissue cultured for 24 h and in cryopreserved-thawed tissue, using two different programmes. We also analysed frozen-thawed samples cultured for 24 h in comparison with untreated fresh fixed control tissue. Immunohistochemical analysis using anti-MAGE-A4, vimentin and CD34 monoclonal antibodies was performed in order to visualize and characterize the cryodamage of the different testicular cells and compartments. The structure of the tissue was evaluated using light microscopy. Qualitative control analysis was performed using transmission electron microscopy. **RESULTS:** No clear structural changes were observed in the fresh, fresh cultured and cryopreserved testicular tissue after using the protocol developed for adult testicular tissue. The programme earlier successfully used for human fetal testicular tissue cryopreservation caused more tissue damage. **CONCLUSIONS:** Pre-pubertal testicular tissue from boys facing gonadotoxic treatment survives cryopreservation, can be cryobanked and hopefully used for fertility preservation. Slow programmed freezing with DMSO as a cryoprotectant is efficient in maintaining the spermatogonia, Sertoli cells and stromal compartment during freezing, thawing and tissue culture.

**Key words:** cryopreservation/fertility preservation/pre-pubertal boys/spermatogonia/testicular tissue

## Introduction

Testicular tissue cryopreservation would be an important technique for fertility preservation in pre-pubertal boys, who do not yet have sperm in the ejaculate and who are scheduled to undergo gonadotoxic treatment (Hovatta, 2001). If the boy already has spermatozoa in his semen, it is best to freeze sperm (Kliesch *et al.*, 1996; Coulson *et al.*, 2001; Bahadur *et al.*, 2002). Cryopreservation of semen and spermatozoa is a well-developed technique, routinely used in everyday practice in infertility laboratories. But for those boys who cannot produce an ejaculate containing spermatozoa, an optimized method of testicular tissue cryopreservation is needed.

Cryopreservation of testicular cell suspension has been proposed as an alternative method suitable for patients with azoospermia and young patients who are not yet producing sperm (Brook *et al.*, 2001). Human fetal testicular tissue has been successfully cryopreserved in a study regarding tissue transplantation in infertile men with hypogonadism (Grischenko *et al.*, 1999). For pre-pubertal boys, when full spermatogenesis is not yet ongoing, it is essential to store the spermatogonia (SG) and the neighbouring cells as undamaged integrated tissue (Ehmcke *et al.*, 2006). Preservation of Sertoli cells (SCs) and cell-to-cell contacts in testicular tissue have proved to be important for subsequent maturation of SG (Ogawa *et al.*, 2005).

There are only a few reports regarding cryopreservation of testicular tissue from pre-pubertal boys. Bahadur *et al.* (2000) reported two cases in which pieces of testicular tissue had been harvested from 8- and 13-year-old boys prior to chemotherapy and cryopreserved by means of different protocols. Survival of the tissue was not analysed. Recently, a method developed for successful cryopreservation of human ovarian tissue (Newton *et al.*, 1996) has been reported as relevant for cryopreservation of testicular tissue in boys with cryptorchidism (Kvist *et al.*, 2006).

How to use the frozen-thawed spermatozoa in infertility treatment in adult life is an important issue, which still requires both basic and clinical research. The alternatives have been studied and discussed in experimental design. *In vitro* spermatogenesis would be the safest option for boys suffering from haematological malignancies which might be re-transmitted by transplantation (Hovatta, 2001; Jahnukainen *et al.*, 2001). Spermatogenesis *in vitro* is under development, but not yet available. Autologous transplantation of SG stem cells would be a very good option for those men whose risk for re-transmission of the malignancy though the graft is low. There are promising results in experimental animal studies, even though the optimal method even there still has to be defined (Dobrinski *et al.*, 2000; Schlatt *et al.*, 2002; Goosens *et al.*, 2003; Gassei *et al.*, 2006; Geens *et al.*, 2006; Honaramooz *et al.*, 2007; Schlatt *et al.*, 2006). The safety of cryobanked immature gametes as regards imprinting is also an issue to be studied experimentally.

The aim of the present study is to investigate whether cryopreservation methods developed for fetal (Keros, 1999) and AHTT (Keros *et al.*, 2005) are suitable for cryopreservation of pre-pubertal human testicular tissue. The major differences between the protocols have been the cooling rates before and after the seeding point (at  $-8^{\circ}\text{C}$ ). The cooling rate was faster in the cryopreservation programme originally developed with the aim of maintaining the integrity and functional capacity of the fetal Leydig cells (Keros, 1999). It was slower in the protocol developed for adult testicular tissue aiming at preservation of SG. Similar cryopreservation media containing 0.7 M dimethyl sulphoxide (DMSO) as a cryoprotective agent were used for both of the earlier mentioned protocols.

In the present study, we also carried out immunohistochemical detection of different cells for the evaluation of the cryodamage and antigenicity of testicular tissue after cryopreservation. SG and SCs were recognized by MAGE-A4 (Keros *et al.*, 2005) and vimentin staining, respectively. The CD34 positivity of the cells forming a reticular network around the seminiferous tubules (STs) and Leydig cells (Kuroda *et al.*, 2004) was used for visualization of the testicular stroma.

## Materials and methods

Five pre-pubertal or young pubertal boys facing cancer treatment or bone marrow transplantation underwent testicular biopsy as a fertility-preserving procedure. The option for fertility preservation was proposed for patients and their families when the planned treatment

included irradiation into the lower pelvic area or total body irradiation and/or high-dose chemotherapy as a conditioning treatment prior to stem cell transplantation. These therapies are known to carry high risk of permanent infertility (Thomson *et al.*, 2002). A 14-year-old boy with thalassaemia was suggested to ejaculate a semen sample before stem cell transplantation, but he was not able to produce it. Hence, this boy was offered testicular biopsy. The boys and/or their parents were informed about the research stage of this study and possible risks of the procedure. They were also told that we could not guarantee spermatogenesis after the treatment. The parents signed an informed consent form, and oral consent was obtained in addition from the 10- and 14-year-old boys. The Ethics Committee of the Karolinska Institutet in Karolinska University Hospital Huddinge has approved the study.

The boys, aged 2–14 ( $7.2 \pm 5.2$ , mean  $\pm$  SD), suffered from (i) rhabdomyosarcoma (aged 8); (ii) acute lymphoblastic leukaemia (aged 10); (iii) acute myeloid leukaemia (aged 2); (iv)  $\beta$ -thalassaemia major (aged 14); (v) juvenile myelomonocytic leukaemia (aged 2). The planned gonadotoxic cancer treatment for Patient 1 was chemotherapy and lower pelvic irradiation and for Patients 2–5, stem cell transplantation. Testicular tissue was obtained by open biopsy carried out under general anaesthesia in connection with operation for tumour ablation (Case 1) or deep venous catheter placing (Cases 2–5). The healing of skin and testicular scars after testicular biopsy was followed-up by clinicians. No severe complications were detected.

The total size of the biopsied tissue was about  $1-2 \times 2-7 \times 9-10$  mm. The median volume of the obtained testicular tissue was  $44 \text{ mm}^3$  and ranged from 2 to  $140 \text{ mm}^3$  ( $52 \pm 53 \text{ mm}^3$ /mean  $\pm$  SD).

The tissue was collected into pre-equilibrated sperm preparation medium (MediCult, Jyllinge, Denmark) and transported at room temperature to the Fertility Unit of our hospital for subsequent cryopreservation (Figure 1). One small piece ( $1-2 \text{ mm}^3$ ) from the biopsy tissue was mechanically disaggregated and examined in direct microscopy for predicting the presence of testicular spermatozoa. No spermatozoa were found in any of these disaggregated samples. In histology later, only SG and SCs were seen in STs of the investigated testicular tissue, obtained from all of the patients.

Preparation of the tissue for cryopreservation was usually initiated  $\sim 5-10$  min after the biopsy. After meticulous washing in Hanks' balanced salt solution (HBSS) (Gibco<sup>TM</sup>, Invitrogen Corporation,

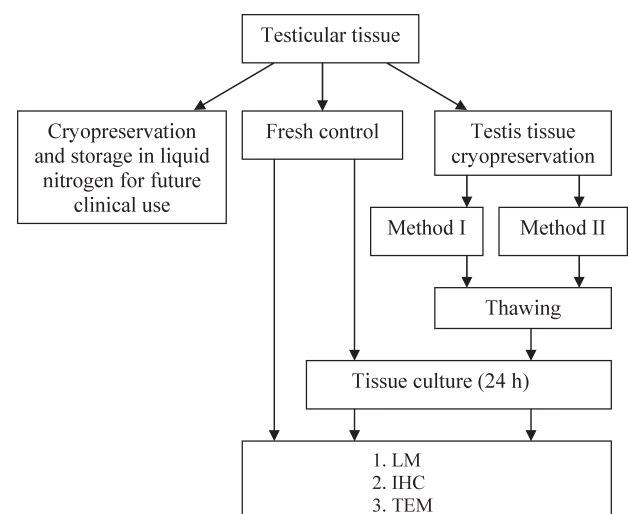


Figure 1. Study design.

Scotland, UK) to remove the blood as well as possible, four pieces of tissue of  $\sim 1\text{--}4\text{ mm}^3$  in size were cut from the biopsy sample and used for diagnostic and research purposes (Figure 1). One piece of tissue was fixed for histology and subsequently used as a fresh control. Another one was cultured for 24 h before fixation and used as a fresh cultured control. The two remaining pieces of tissue were frozen using two different programmes. After storage in liquid nitrogen, they were thawed, cultured for 24 h and fixed for morphometric evaluation.

In three patients, the amount of tissue obtained also allowed us to carry out transmission electron microscopy (TEM). In these cases, one piece of tissue of  $\sim 0.5\text{--}1\text{ mm}^3$  was treated in parallel with a sample for light microscopy (LM).

The main part of the biopsied testicular tissue in all cases was cut into pieces ( $\sim 2\text{--}5\text{ mm}^3$ ), cryopreserved and stored in the cryobank for later clinical use.

### Cryopreservation

The tissue pieces were placed in 1.8 ml cryovials (NUNC, Life Technologies, Roskilde, Denmark) containing 1.5 ml of cryoprotectant medium, which consisted of 5% DMSO (Sigma-Aldrich, Sweden AB) and 5% human serum albumin (HSA) solution (Vitrolife, Göteborg, Sweden) diluted in HBSS. Equilibration was performed at  $+4^\circ\text{C}$  for 30 min. Subsequently, the samples were cooled in a programmable CL863 freezer (Cryologic PL, Australia). Cooling was started at  $+4^\circ\text{C}$ .

Two different programmes for cryopreservation of testicular tissue samples were compared in this study.

Programme 1 (Cryo I) was the one developed for cryopreservation of AHTT, with the main aim of preserving existing SG (Keros *et al.*, 2005). The cooling rate was  $1^\circ\text{C min}^{-1}$  with holding at  $0^\circ\text{C}$  for 5 min, followed by cooling at  $0.5^\circ\text{C min}^{-1}$  until  $-8^\circ\text{C}$ . At this temperature, seeding was initiated manually. After holding for 10 min, the vials were frozen to  $-40^\circ\text{C}$  at a rate of  $0.5^\circ\text{C min}^{-1}$ , held for 10 min and the programme was continued to  $-70^\circ\text{C}$  at  $7^\circ\text{C min}^{-1}$ , with subsequent plunging into liquid nitrogen.

Programme 2 (Cryo II) was the same as that used for cryopreservation of human fetal testicular tissue (Keros, 1999). This protocol was developed mainly with the aim of preservation of Leydig cells. Briefly, after cooling at a rate of  $1^\circ\text{C min}^{-1}$  to the seeding temperature ( $-8^\circ\text{C}$ ), manual initiation of seeding and 10 min holding at this temperature, the samples were frozen at a rate of  $10^\circ\text{C min}^{-1}$  to  $-80^\circ\text{C}$  and plunged into liquid nitrogen ( $-196^\circ\text{C}$ ).

The samples were thawed in a water bath at  $37^\circ\text{C}$  until the ice melted, washed in sterile HBSS and placed in culture for recovery.

### Tissue culture

One-day culture was performed to check the viability of the tissue samples after cryopreservation. Following thawing and rehydration procedures, the tissue pieces were placed in IVF 4-well plates (Becton Dickinson Labware Europe, Le Pont de Claix, France) with 0.5 ml pre-equilibrated culture medium consisting of  $\alpha$ MEM, HSA (15%), L-glutamine, insulin-transferrin-sodium selenite (ITS), antibiotic/antimycotic solution (all listed substances manufactured by Life Technologies-Gibco, Paisley, Scotland) and 8-bromo-cGMP (Sigma, St Louis, MO, USA) (Keros *et al.*, 2005). Tissue culture was performed in a humidified incubator (Galaxy, UK) at  $33^\circ\text{C}$  in 5%  $\text{CO}_2$  in air. After recovery for 24 h, the tissue was fixed for subsequent morphological examination. One piece of fresh tissue was also cultured using the same system and used as fresh cultured control.

In one patient, two small pieces of tissue cryopreserved using protocol I were cultured for 10 days. Afterwards, immunohistochemistry (IHC), LM and TEM were performed.

### LM and TEM

For LM, pieces of tissue were transferred to Bouin's solution for 4–6 h at  $4^\circ\text{C}$  and afterwards dehydrated in 70% ethanol, embedded in paraffin (Paraplast, Sherwood Medical, St Louis, MO, USA) and sectioned at a thickness of  $4\text{ }\mu\text{m}$ . One slide with 6–10 sections was stained in haematoxylin (HTX) and eosin. The unstained ones were used for IHC.

Next, all samples were coded so that the observer would be blind to their origin, and semiquantitative double evaluation was performed using (i) a digital image analysis system (Easy Image Mätning, Bergström Instruments, Stockholm, Sweden) connected to an inverted microscope (Nikon, Bergström Instrument) and (ii) a conventional light microscope (Nikon ECLIPSE E 400). Images were taken with a digital camera (Nikon, COOLPIX950) at final magnifications of  $\times 200$  and  $\times 400$ .

For TEM, small samples of  $\sim 0.5\text{--}1.0\text{ mm}^3$  were placed in special TEM fixation solution (pH 7.4) consisting of 2% glutaraldehyde and 0.5% paraformaldehyde, 0.1 M sucrose, 3 mM calcium chloride and 0.1 M sodium cacodylate buffer. Ultrathin sections ( $50\text{--}60\text{ nm}$ ) were treated with 2% uranyl acetate and lead citrate and examined in a Tecnai 10 (Fei, the Netherlands), and digital images were taken using a mega view-III camera (SIS-company, Munster, Germany) at magnifications between  $\times 1650$  and  $\times 30\,000$ .

### Immunohistochemistry

Immunohistochemical analysis was performed for visualization and characterization of cryodamage in the different testicular cells and compartments. SG were recognized by using 57B anti-MAGE-A4 mouse monoclonal antibody (1:50), kindly donated by Dr Giulio C. Spagnoli (University of Basel, Basel, Switzerland).

SCs were detected by vimentin staining (mouse monoclonal antibody, code M 0725, 1:1000, Dako Cytomation, Glostrup, Denmark). Peritubular cells and stromal tissue were stained using anti-CD34 mouse monoclonal antibody (code M 7165, 1:100, Dako Cytomation).

No antigen retrieval was required. IHC was performed using avidin–biotin peroxidase complex (Vector Laboratories, CA, USA) protocols. All sections were counterstained with HTX. Use of non-immune serum and omission of the second antibody were used as control procedures.

Pieces of testicular tissue fixed, embedded and sectioned using the technique described earlier, were evaluated as regards the structural integrity of the tissue.

Depending on the original size of the samples, two to six sections were used for IHC, using each antibody. To avoid double counting of the same SG, only each second section was assessed, and thus one to three sections from each sample were evaluated after staining in IHC.

### Morphological evaluation

Quantitative evaluation of the structural changes in testicular tissue was performed by studying morphology in four groups: samples frozen–thawed by means of the two protocols (Cryo I and Cryo II), fresh samples cultured for 24 h (fresh/cultured) and fresh samples fixed directly after the biopsy procedure (Fresh).

For assessment of cryodamage of pre-pubertal testicular tissue, serial sections of tissue pieces were analysed and the following were counted: number of cross-sections, number of STs, number of SG and the area of the examined cross-sections. The results were presented as total number and total area.

The areas of the examined sections were measured using a digital image analysis system (Easy Image Mätning, Bergström Instrument, Stockholm, Sweden) connected to an inverted microscope (Nikon, Bergström Instrument).



The total number of STs was expressed as the number of STs per mm<sup>2</sup> section area. The percentages of STs with an intact undamaged structure (UD), signs of central necrosis (CN) and those totally damaged (TN; total necrosis) (Figure 6A) were evaluated in each patient and presented as mean  $\pm$  SD.

The total number of SG was counted in each examined section. The following parameters were counted: number of SG with undamaged structure (SG/UD), SG detached from neighbouring SCs for >50% of the length of the cell border (SG/DT) and number of degenerated SG (SG/DG). Degenerated cells were defined as cells with >50% vacuolization of the cytoplasm and/or a dark pyknotic nucleus. Finally, the numbers of detached and degenerated SG (DT/DG) were counted. The number of SG in each group was divided by the total number of SG in the investigated sample and presented as a mean percentage ( $\pm$ SD).

Stroma, which consists of interstitial tissue and tubular walls, was evaluated separately, using a scoring system. Normal stroma was given the score 2 (undamaged), stroma with <50% damage was given the score 1 (influenced) and stroma with >50% damage was given the score 0 (damaged). The number of sections in each score group was divided by the total number of sections investigated and expressed as a percentage.

The numbers of SG detected by IHC were counted and the corresponding areas measured, thus giving the number of IHC-positive cells per mm<sup>2</sup>. This was used to compare the numbers of SG in different treatment groups.

### Statistical analysis

The sample from Patient 2 was excluded from the evaluation because the piece of testicular tissue was extremely small. Only three STs, which contained two SG, existed in this sample. Overall morphological evaluation and statistical analysis were performed with the samples obtained from four patients.

All data are expressed as a mean  $\pm$  SD. Independent grouping variables were compared using the Mann–Whitney *U*-test and STATISTICA software (StatSoft Inc., Tulsa, OK, USA). Results were considered statistically significant at  $P < 0.05$ .

## Results

### LM and TEM

LM investigation of the tissue showed no structural differences between the fresh, fresh/cultured (pictures not shown because of similarity in structure) and frozen–thawed (protocol I) tissue (Figure 2, columns Fresh and Cryo I). MAGE-A4 immunostaining and HTX staining showed no differences in SG between cryopreserved–thawed samples from the Cryo I group and fresh controls (Figure 2). Vimentin staining showed clear integrity of the SCs. However, a lower number of SG were visualized in the Cryo II group when compared with the fresh and Cryo I groups (Figure 2, column Cryo II). STs with central and total necrotic changes of the cells were seen more frequently. It was also easier to recognize structural changes, such as vacuoles (V) or detachment of the SG, using MAGE-A4 staining (Figure 2, column Cryo II, row MAGE-A4).

CD34 immunostaining showed a testicular stromal network without signs of damage in all study groups.

Qualitative analysis performed by means of TEM showed well-preserved ultrastructure in the SG (Figure 3) and SCs (Figure 4) in the fresh (Figure 3A and A<sub>1</sub>), fresh/cultured

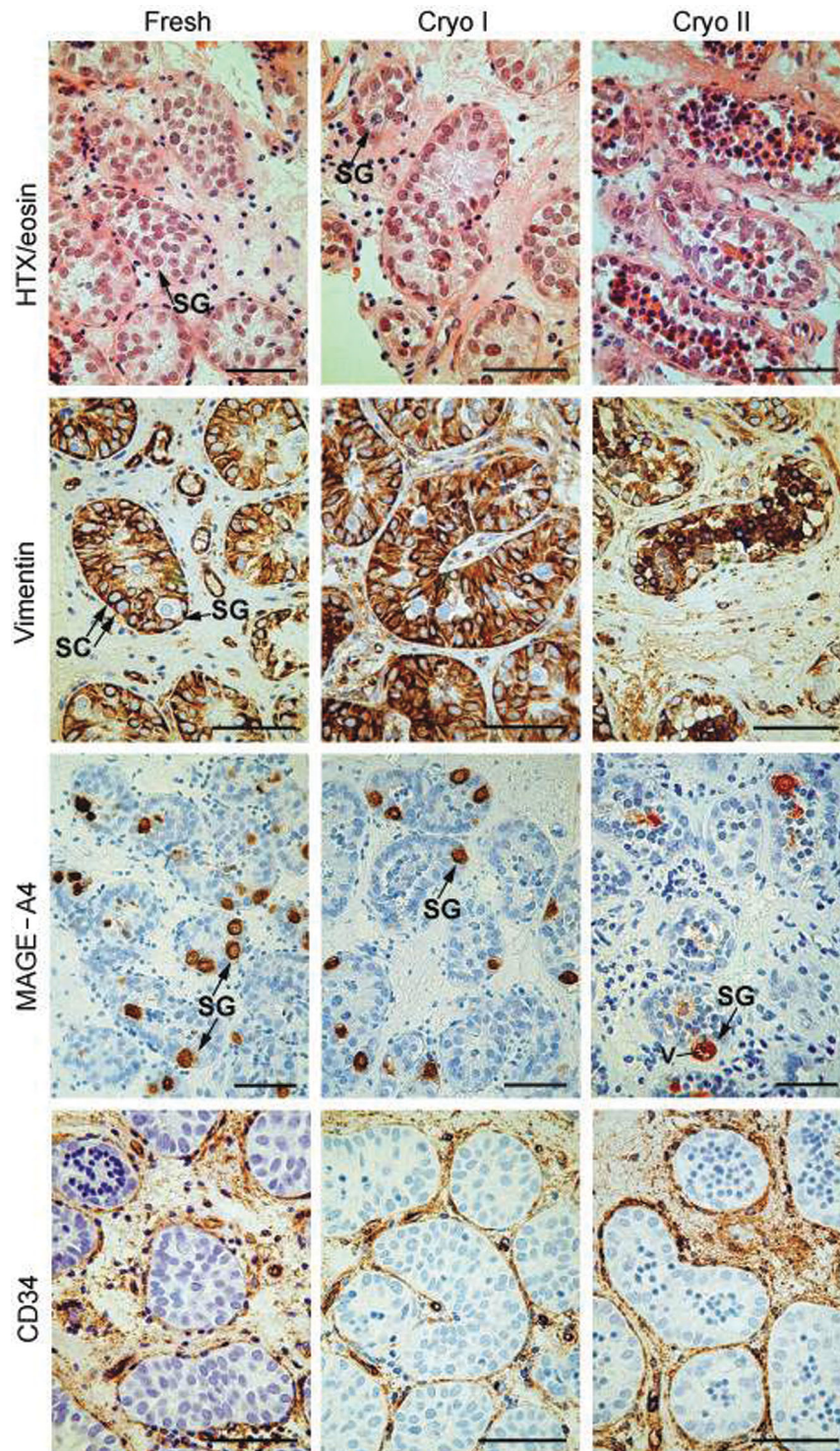
(Figure 3B and B<sub>1</sub>) and Cryo-I-treated pre-pubertal testicular tissue (Figure 3C and C<sub>1</sub>). In general, SG were characterized by good integrity of the nuclei (N): morphology of euchromatin and heterochromatin, nucleolus (Nc) and the nuclear membrane (Nm). In some cells, normal nuclear division was seen (Figure 3B). The freezing and thawing procedure did not cause increased damage of the cell membrane (Cm). The integrity of the cytoplasm and its components was well preserved. In most samples, mitochondria (M) displayed a normal ultrastructure, as did the endoplasmic reticulum and Golgi apparatus. Clear attachment of SG and SCs to the basement membrane (Bm) was observed in the different study groups (Figures 3A–D and 4). Cell-to-cell contacts between SGs and SCs were well preserved (Figure 3C and C<sub>1</sub>). However, empty spaces, also presented in the fresh tissue (Figures 3A, A<sub>1</sub> and 4A), were slightly increased in size in fresh/cultured (Figures 3B, B<sub>1</sub> and 4B) and cryopreserved (protocol I) samples (Figures 3C, C<sub>1</sub> and 4C). Tight junctions between SCs were also clearly visible (Figure 4C and D), indicating normal cell-to-cell contacts. Necrotic cells were present in the middle of some STs in the three investigated groups. However, in general, only minor structural changes were noted when comparing the three groups.

More vacuoles were observed in the tissues treated using protocol II (Figure 3D). Increased vacuolization was more frequently seen in the cytoplasm and nuclei of SG and SCs when compared with fresh control samples. The sizes of the vacuoles were sometime large enough to cause cell necrosis/death. The integrity of the cytoplasm was more influenced, and the mitochondria were characterized by dilated cristae (Figures 3D<sub>1</sub> and 4E).

In our experiments, breakage of the attachment of the cells to the basal membrane of the lamina propria (LP), which is a specific sign of cryodamage, was not seen in the majority of the samples in any investigated group, even in the Cryo II group (Figure 4F). An increased number of empty spaces between cells was occasionally seen. However, attachment of SG and SCs was preserved in most of the sections.

The stroma, regardless of the protocol used, showed normal undamaged morphology of the layers of LP of STs and interstitial tissue in most cases.

SG were present in all pieces of cryopreserved tissue cultured for 10 days after thawing. Intact SG were found both in the paraffin sections (Figure 5A–D) and in TEM (Figure 5E). All surviving testicular cells and the tissue in general looked healthy. No differences were seen in the tissue structures (Figure 5A). STs that had been initially damaged were totally degenerated after 10 days of culture (Figure 5C). Larger sized empty spaces between neighbouring cells were seen (Figure 5E). However, cell-to-cell contacts between SG and SCs were clearly seen (Figure 5E and F). Attachments of SG (Figure 5F and G) and SCs (Figure 5H) to the basal membrane of the STs were preserved. The structure of the surviving cells was not damaged. Cell and nuclear membranes were not interrupted (Figure 5E–H). Mitochondria and other organelles of the cytoplasm had a distinct morphology (Figure 5G and H).



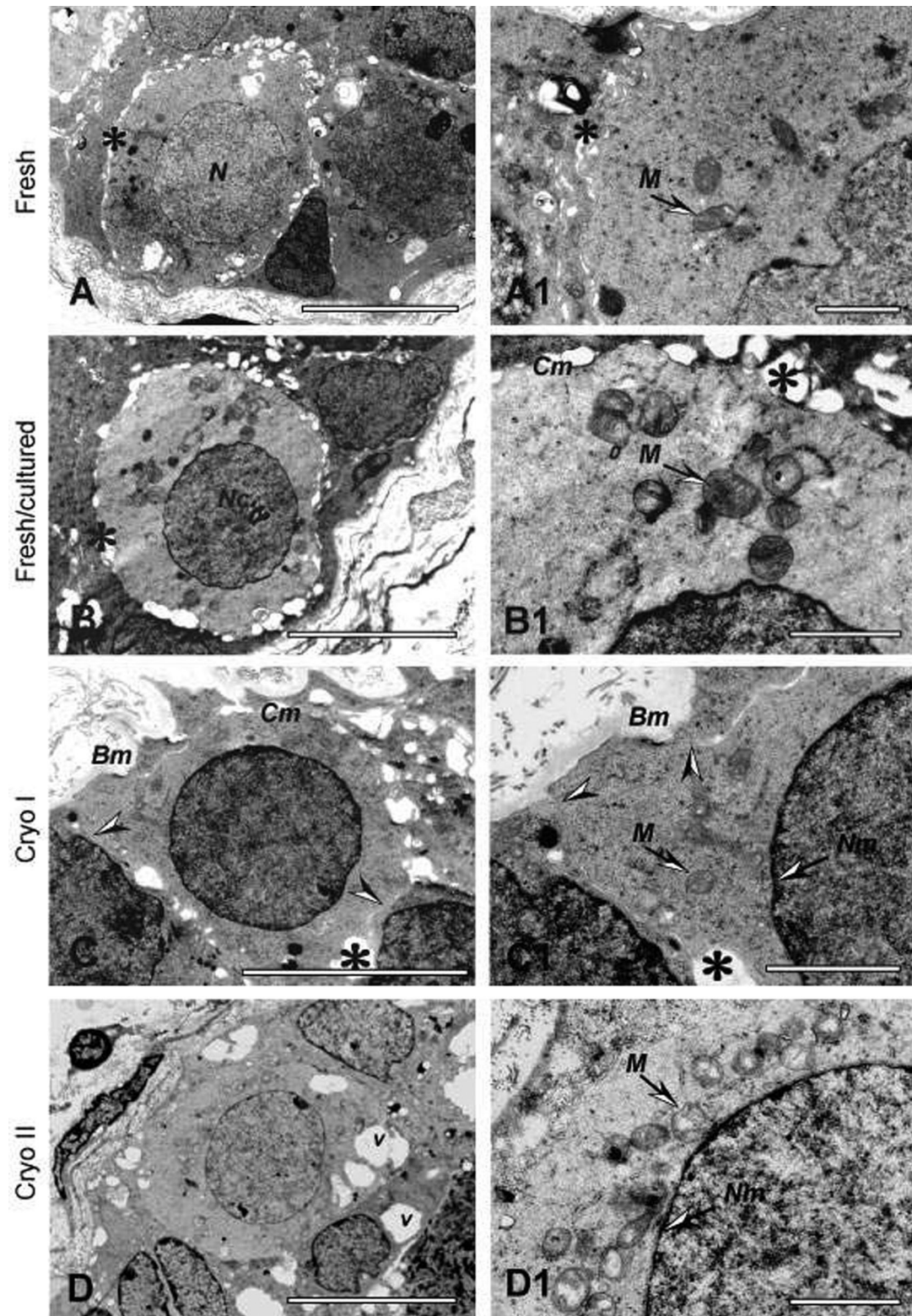
**Figure 2.** Light microscopy morphology (HTX/eosin) and immunohistochemistry (IHC) (vimentin, MAGE-A4, CD34) of freshly fixed human pre-pubertal testicular tissue (left panel), tissue cryopreserved using protocol I (middle) and tissue cryopreserved using protocol II (right panel). SC, Sertoli cells; SG, spermatogonia. All presented samples were obtained from the same patient, a 10-year-old boy. Tissues from fresh and Cryo I groups exhibit similar structure and antigenicity. Increased number of seminiferous tubules (STs) with central or total necrosis is observed in tissue from the Cryo II group. Vacuoles in the SG are well defined in MAGE-A4-stained tissue samples. Original magnification  $\times 400$ , scale bar = 50  $\mu\text{m}$ .

Samples visualized by means of vimentin and CD34 (Figure 5B and C) showed the same intensity of staining as in control tissue. Detection of SG using anti-MAGE-A4 (Figure 5D) gave results similar to those in fresh control cells.

#### **Morphological evaluation**

The effects of cryopreservation using two different programmes, and *in vitro* culture, on survival of pre-pubertal testicular tissue are given in Figure 6. Twenty-four-hour culture



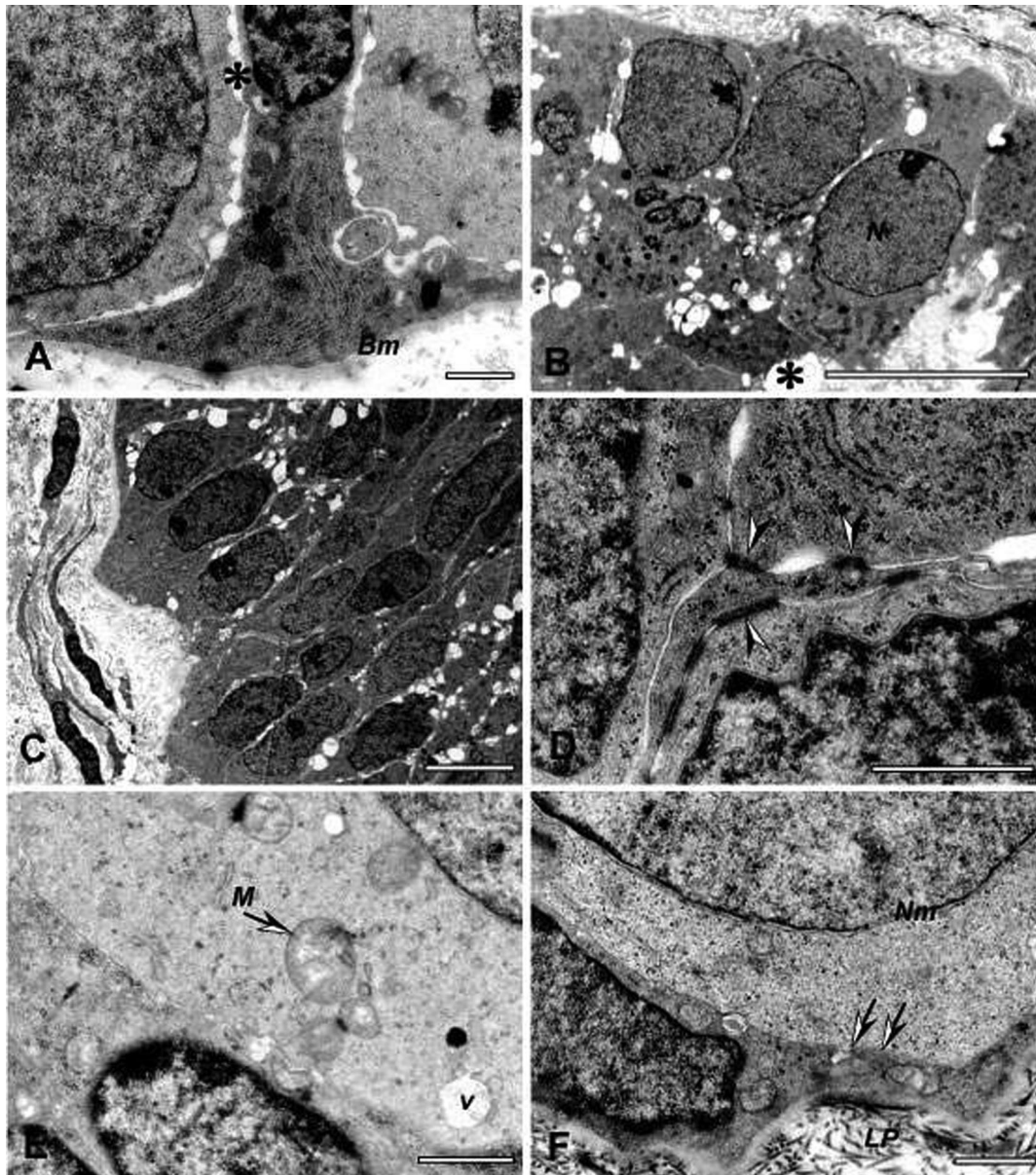


**Figure 3.** Transmission electron microscopy (TEM) of SG in pre-pubertal human fresh (A and A1), fresh/cultured (B and B1), Cryo I (C and C1) and Cryo II (D and D1) testicular tissue. N, nuclei; \*, empty space between cells; M, mitochondria; Nc, nucleolus; Cm, cell membrane; Bm, basement membrane; Nm, nuclear membrane; V, intracellular vacuoles; arrowheads indicate contacts between SG and SCs. Toluidine blue staining. Scale bar = 10  $\mu$ m (A–D), scale bar = 2  $\mu$ m (A1–D1).

did not influence the integrity of the tissue. The numbers of ST with intact structures were slightly increased after culture ( $77 \pm 4\%$ ) when compared with fresh tissue ( $71 \pm 7\%$ ).

The proportions of ST with signs of central necrosis (CN: fresh  $22 \pm 3\%$ ; fresh/cultured  $19 \pm 5\%$ ) and total necrotic changes (TN: fresh  $7 \pm 4\%$ ; fresh/cultured  $4 \pm 1\%$ ) were





**Figure 4.** TEM of SCs from pre-pubertal human testicular tissue. Fresh (A), fresh/cultured tissue (B), tissue from the Cryo group I (C and D) and tissue from the Cryo group II (E and F). SCs attached to the basement membrane (Bm) with some empty spaces (\*) between SG (A) and SCs (B and C). SCs in fresh/cultured tissue (B) and in tissue from the Cryo I protocol (C), similar to fresh controls, show intact structures of nuclear and cytoplasmic components and attachment to Bm and neighbouring cells. Higher magnification shows well-defined tight junction (arrow heads) between SCs in Cryo-I-preserved tissue (D). (E) SCs (lower) and SG (upper) from Cryo II-preserved tissue containing mitochondria with dilated cristae (M) and intracellular vacuoles (V). Some SCs and SG in tissue cryopreserved by means of protocol II also demonstrate intact nuclear structures (N), good attachment to Bm of Lamina propria (LP) and well-defined cell membrane (arrows) and nuclear membrane (Nm) in an SG cell (F). Toluidine blue staining. Scale bar = 1  $\mu$ m (A, D, E and F) and scale bar = 10  $\mu$ m (B and C).

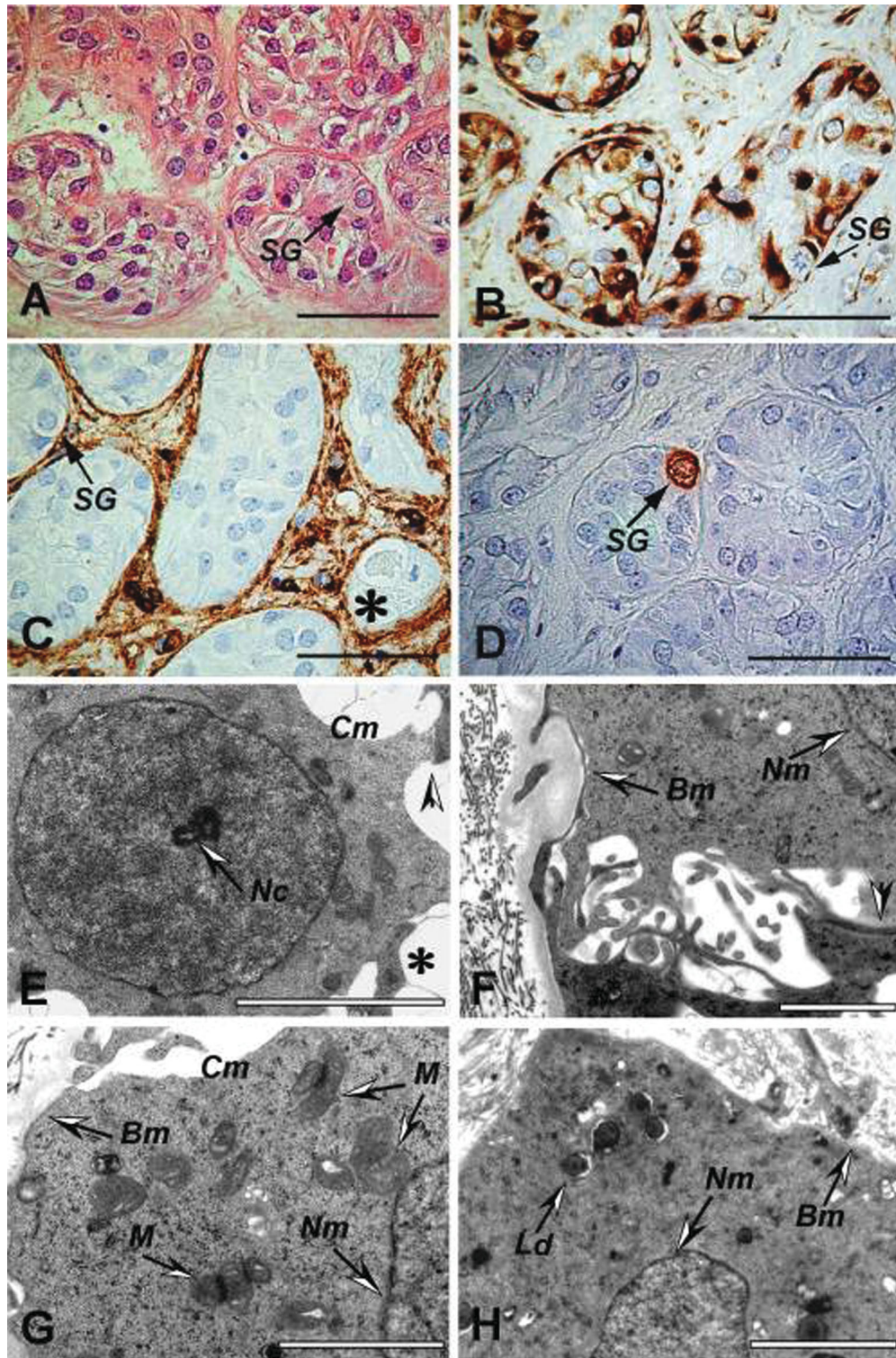
slightly decreased in the cultured tissue. However, these changes were not significant and, in general, the structure of the cultured tissue was similar to that in fresh non-cultured control tissue (Figure 6B).

The results obtained after cryopreservation using the protocol developed for human adult testicular tissue (Cryo I) were identical to those in the fresh and fresh/cultured groups. The majority ( $70 \pm 7\%$ ) of STs was characterized as undamaged, and in  $24 \pm 4\%$  of the tubules, necrotic cells were presented in the centre. Total necrosis of the ST cells was noticed in  $6 \pm 4\%$  of the STs.

Significant changes were observed in the tissue cryopreserved using programme II. The percentage of STs with intact morphology had decreased to  $20 \pm 14\%$ , and the proportions of tubules with central and total necrosis of the cells (CN/ST  $44 \pm 5\%$  and TN/ST  $37 \pm 10\%$ ) were significantly higher in comparison with fresh samples, fresh/cultured samples and samples cryopreserved using programme I (Figure 6B).

The survival of SG is shown in Figure 6C. The percentage of SG with normal undamaged morphology in the control, fresh/cultured and Cryo I groups ( $93 \pm 2$ ,  $83 \pm 1$  and  $94 \pm 1\%$ ,



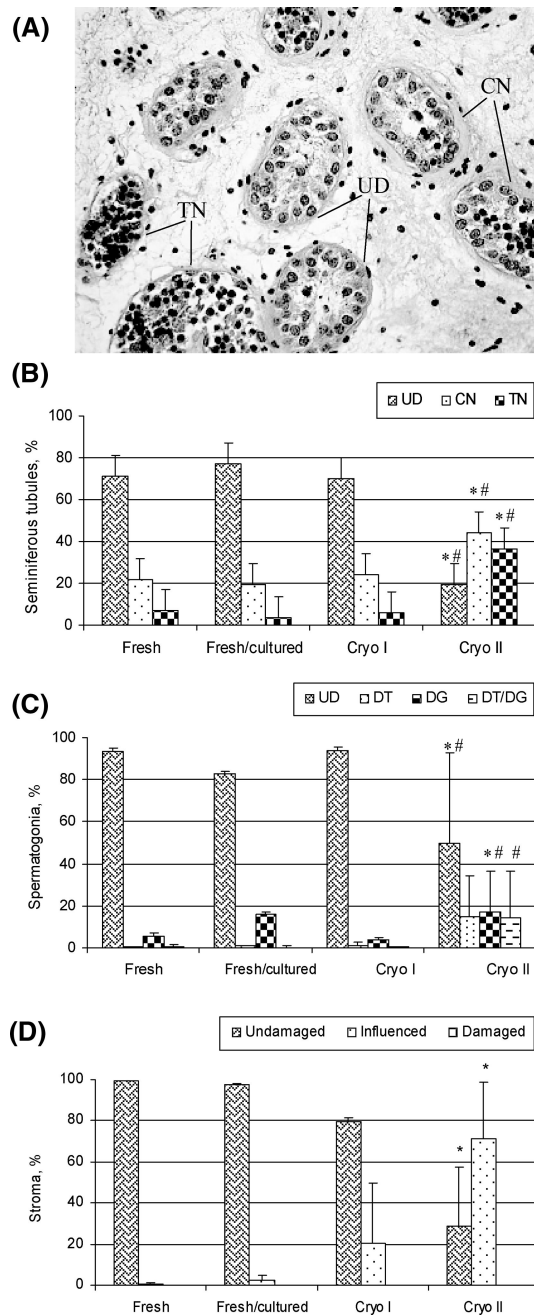


**Figure 5.** LM (A–D) and TEM (E–H) of cryopreserved tissue followed by 10 days of culture, stained with HTX/eosin (A) and using vimentin (B), CD34 (C) and MAGE-A4 (D). TEM of SG showing cell–cell contact (arrow head) and some empty space between cells (\*) (E). SG cell attached to the basement membrane (Bm) and tight cell–cell contact (arrow head) (F). SG cell containing well-preserved mitochondria (M) and nuclear membrane (Nm) (G). SC with intact nuclear membrane and some lipid droplets (Ld) attached to the Bm (H). SG = spermatogonia, Nc = nucleolus; Cm, cell membrane. Original magnification  $\times 400$ ; scale bar,  $50\ \mu\text{m}$  (A–D), scale bar,  $5\ \mu\text{m}$  (E and H) and scale bar,  $2\ \mu\text{m}$  (F and G).

respectively) was similar, whereas in the Cryo II group, the proportion of intact cells was significantly decreased ( $50 \pm 43\%$ ). Detachment of SG from neighbouring SCs was

higher in the samples cryopreserved using programme II ( $15 \pm 20\%$ ). However, no statistical difference was noticed between the samples in the various study groups.





**Figure 6.** The effect of cryopreservation and 24-h tissue culture on the structures of human pre-pubertal testicular tissue in the fresh, fresh/cultured, Cryo I and Cryo II groups. Data presented as mean  $\pm$  SD. (A) Testicular tissue cryopreserved using the Cryo II protocol, demonstrating structural changes in the STs. UD, undamaged structure of ST; CN, ST with signs of central necrosis and TN (total necrosis), totally damaged morphology of ST. (B) Structural changes in STs in the testes in pre-pubertal boys. (C) Percentages of SG with undamaged morphology (SG/UD), SG detached from neighbouring cells (SG/DT), degenerated SG (SG/DG) and SG detached and degenerated at the same time, related to the total number of SG in the investigated sample. (D) Structural integrity of the stroma, presenting intact 'undamaged' morphology, 'influenced', with  $<50\%$  damage and damaged, with  $>50\%$  damage of the tubular wall and interstitial tissue. Good survival of the testicular stroma is noted. No area with  $>50\%$  damage was observed. Results were considered statistically significant at  $P < 0.05$ . \*, significant difference versus native tissue; #, significant difference versus samples cryopreserved using programme I.

The percentage of degenerated SG was significantly increased in the tissue cryopreserved by means of protocol II ( $14 \pm 22\%$ ) when compared with the fresh and Cryo I groups ( $6 \pm 1$  and  $4 \pm 1\%$ , respectively) (Figure 6C). In the Cryo II group,  $14 \pm 22\%$  of the SG were degenerated and also detached from surrounding cells, this figure being significantly higher than in the Cryo I group ( $0.3 \pm 0.3\%$ ). No statistical difference was observed between the fresh, fresh/cultured and Cryo I groups, where  $<1\%$  of SG were characterized by simultaneous detachment and degeneration (Figure 6C).

No tissue had any signs of necrotic stroma or damage evaluated as grade 0 (Figure 6D). An undamaged stromal structure was present in  $99.49 \pm 0.88\%$  of the fresh samples,  $97 \pm 2\%$  of the fresh/cultured samples and  $80 \pm 29\%$  of samples in the Cryo I group. In the Cryo II group, the percentages of undamaged ( $29 \pm 28\%$ ) and influenced stroma ( $71 \pm 28\%$ ) were significantly lower than in fresh control tissue. No significant difference was observed when the proportion of influenced stroma was compared in the fresh, fresh/cultured and Cryo I groups.

No significant difference was observed in the distribution of SG per  $\text{mm}^2$  of testicular tissue, counted in the four investigated groups after staining using HTX/eosin and after immunohistochemical staining using antibodies against MAGE-A4, vimentin and CD34 (Figure 7).

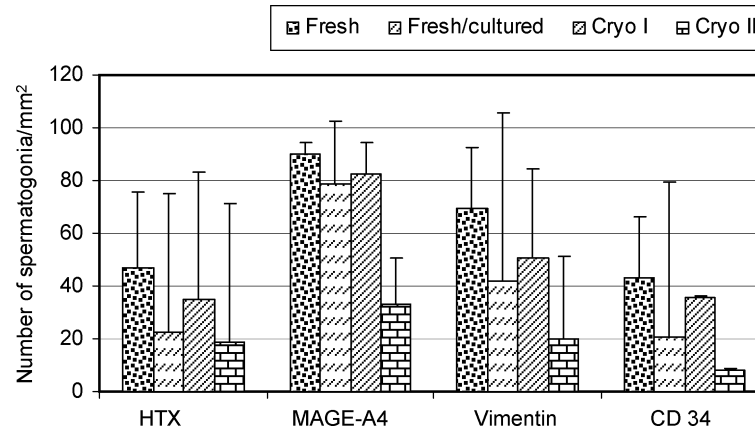
## Discussion

We have optimized a cryopreservation method for freezing of testicular tissue in pre-pubertal boys.

Banking of testicular tissue in pre-pubertal boys before gonadotoxic treatment is a crucial step in fertility preservation (Hovatta, 2003). In the present study, we intended to find an optimal method for cryopreservation of testicular tissue in pre-pubertal boys undergoing gonadotoxic treatment. For this reason, two protocols, originally developed for human fetal and adult testicular tissue cryopreservation, were compared.

In this study, testicular tissue was obtained from five patients undergoing cancer treatment, including lower pelvic irradiation or bone marrow transplantation, with total body irradiation or busulfan in the conditioning procedure. The patients were at high risk of permanent infertility. Testicular biopsies for fertility preservation were therefore ethically justified (Tournaye *et al.*, 2004). For pubertal boys, who are too young to ejaculate, cryopreservation of testicular biopsy and testicular sperm extraction after cryopreservation might be an option for fertility preservation (Hovatta *et al.*, 1996). In the present study, the existence of testicular sperm had been first assessed in direct microscopy. No testicular sperm was observed in any of the samples; therefore, the only option was to freeze testicular biopsy tissue containing SG stem cells.

Owing to the small size of the gonads in children in whom the intense growth phase of the testes has not yet begun, immature gonadal tissue might be at a higher risk for damage by the sampling procedures (Jahnukainen *et al.*, 2006). In the present study, no major operational complications of testicular biopsy



**Figure 7.** Number of SG per mm<sup>2</sup> in sections of testicular tissue after HTX staining and immunohistochemical staining using vimentin, MAGE-A4 and CD34 antibodies. Results are mean  $\pm$  SD.

were observed, which confirms the results of a recent follow-up study in which no adverse long-term effects were associated with testicular biopsy when performed during orchidopexy on cryptorchid boys (Patel *et al.*, 2005).

An optimized amount of gonadal tissue for freezing is an important issue (Tournaye *et al.*, 2004; Jahnukainen *et al.*, 2006). The mean volume of the testicular biopsy tissue (52 mm<sup>3</sup>) among our patients was significantly larger than the mean biopsy size of 0.34 mm<sup>3</sup> reported by Kvist *et al.* (2006). We consider it important to have a sufficient amount of tissue for transplantation or for culture.

The safety and effectiveness of the assisted reproductive technologies are essential issues. It is important to have ethics approval and strong motivation for all procedures included in programmes for fertility preservation in young patients (Tournaye *et al.*, 2004; Bahadur, 2004; Jahnukainen *et al.*, 2006).

Children and their parents should be informed about the experimental stage of the study. However, it is important to inform all patients facing infertility as a side effect of gonadotoxic chemo- and radio-therapies about the options available to preserve their future fertility (Robertson, 2005; Wallace *et al.*, 2005).

We were able to use only small pieces of tissue for investigation because we intended to preserve as much of the biopsy sample as possible for future clinical use. The piece of tissue from one patient was excluded from evaluation because the size was extremely small and only three cross-sections of STs (containing two SG) were found. However, the sample volume obtained from each of the other four patients was sufficient to allow statistically significant evaluation. According to morphological studies, it has been estimated that one testis of a 10-year-old pre-pubertal boy contains  $\sim 83 \times 10^6$  germ cells (Muller and Skakkebaek, 1983). In  $\sim 5\%$  of a pre-pubertal human testis volume obtained in our programme, we probably have enough many cells for recolonization of the tubules.

In our recent study, we compared two existing protocols for cryopreservation of human fetal and adult testicular tissue (Keros, 1999; Keros *et al.*, 2005). Originally, the method for cryopreservation of human fetal testicular tissue was developed with the aim of maintaining the integrity and functional

capacity of the fetal Leydig cells (Keros, 1999). However, undamaged morphology of SG and testicular tissue in general was seen when the tissue was fixed immediately after thawing and examined under LM. We were motivated to test similar technique in cryopreservation of pre-pubertal testis. Preservation of SG was the main idea when the protocol for adult testicular tissue was developed (Keros *et al.*, 2005). In these protocols, DMSO at 0.7 M concentration was used as a cryoprotective agent. Cryoprotectant medium was supplemented with the patient's serum for adult testicular tissue cryopreservation.

Previously, a comparative study was performed in which cryopreservation of human ovarian tissue was carried out with cryoprotectant media containing patient's serum versus serum-free HSA-containing media. No significant difference was observed in the survival of follicles after cryopreservation in the pieces of ovarian tissue (Hreinsson *et al.*, 2003). Taking into consideration these results in our experiments, the patient's serum used in the media for cryopreservation of human adult testicular tissue was replaced with HSA. The use of HSA makes it possible to standardize the cryopreservation medium, to prevent extra pain in young patients because of intravenous injection and to prevent the addition of various medical agents when the blood is obtained under narcosis.

Qualitative examination of the sections in LM showed that both methods in general resulted in good survival of pre-pubertal testicular tissue. The Cryo I programme developed for adult tissue maintained the normal structure better than the second programme, Cryo II, developed for fetal tissue. Histological quantitative evaluation of the morphological characteristics of SG, STs and surrounding tissue demonstrated that the method originally developed for cryopreservation of AHTT gave significantly better results than the method developed for cryopreservation of fetal human testicular tissue (FHTT). A higher percentage of STs containing intact intratubular cells was found in the tissue treated using the AHTT cryopreservation protocol ( $70 \pm 7\%$ ) compared with the FHTT protocol ( $20 \pm 14\%$ ). In LM,  $94 \pm 1\%$  of SG had undamaged morphology in the Cryo I group, compared with  $50 \pm 43\%$  in the Cryo II group.



The small size of the TEM samples did not allow us to perform quantitative evaluation. SCs were the main cell types in the sections, while the numbers of SG were low. However, in TEM, no differences in the structure of the fresh, fresh/cultured and Cryo I samples were seen.

Compared with the fresh control tissue, fresh/cultured tissue had to some degree a better morphology, probably because of recovery of the tissue after temperature shock and the handling procedure. Mostly, good survival of SG, preservation of the cell-to-cell contacts and attachment of SG to the basal membrane were seen.

Samples cryopreserved using protocol II were characterized by increased vacuolization of the cytoplasm of SG and SCs and necrosis of the cells in the centre of the tubules. However, in general, sometimes slightly increased sizes of the empty spaces between cells, but good attachment to the basal membrane, and between neighbouring cells were noted in all cryopreserved and cultured samples.

The results obtained after cryopreservation using two protocols with different cooling and freezing rates differed from each other mainly in the survival of SG. Higher cooling rates before and mostly after the seeding temperature ( $-10^{\circ}\text{C min}^{-1}$ ) were used in the protocol designed for fetal testicular tissue cryopreservation. The number of SG with signs of cryodamage was increased when compared with the protocol for adult testicular tissue cryopreservation. According to our results, it is important to use slow programmed freezing to maintain undamaged morphology of the SG.

The method of long-term culture is widely used for evaluation of cryodamage in tissues. Cells damaged during the process of cryopreservation will no doubt be recognized after tissue recovery in culture. In 1-day culture, they will be characterized by signs of necrosis. However, after culturing for 10 days, those cells will be totally degenerated, whereas undamaged cells will present structural integrity.

We were able to use long-term culture in one case where there was sufficient tissue. Two small pieces of tissue cryopreserved using protocol I, developed for cryopreservation of AHTT, were cultured for 10 days. The SG and SCs which were not degenerated after the freezing–thawing procedure showed undamaged morphology in LM and TEM. Hence, the existence of intact SG and SCs in the pieces of tissue, the presence of cell-to-cell contacts and attachment of the cells to the basal membrane after long-term tissue culture confirmed survival of the cells after cryopreservation.

We did not measure testosterone production by the thawed tissue after 24 h of culture because this would have been too short a time for it. Nevertheless, our previous studies have shown that Leydig cells successfully survive cryopreservation, using both of the presented methods (Keros, 1999; 2005). The quality of fetal tissue after cryopreservation was investigated using LM and long-term tissue culture. It was shown that in most cases, when the ischaemia time before cryopreservation was  $<6$  h, the Leydig cells had intact structures and produced high levels of testosterone in culture (Keros, 1999). In addition, after long-term storage in liquid

nitrogen, thawed human fetal testicular tissue has been effectively used for correction of hormonal status in patients with some forms of infertility and hypogonadism (Grischenko *et al.*, 2003). Transplantation of cryopreserved fetal testicular tissue under the skin induced a rise in testosterone concentration in the patient's blood serum and also improved the quality of the sperm and the general somatic condition of the patient (Grischenko *et al.*, 1999). Studying the function of Leydig cells after cryopreservation of pieces of AHTT showed their ability to produce testosterone in culture. Cryopreserved and cultured adult Leydig cells also maintained their morphology in LM and TEM (Keros *et al.*, 2005). These data indicate good survival of Leydig cells cryopreserved in pieces of tissue. Hormone production *in vitro* by pre-pubertal testicular tissue after cryopreservation has recently been reported (Kvist *et al.*, 2006). All these data suggest that Leydig cells are quite resistant to cryodamage and they maintain their structural and functional integrity after cryopreservation.

In spite of maintenance of morphological integrity after successful cryopreservation, *ex vivo* manipulation of the germ cells may cause functional disturbances (Russell and Brinster, 1996). Abnormal imprinting pattern is suggested to be possibly after germ cell manipulation (Dean *et al.*, 1998). Nevertheless, Shinohara *et al.* (2006) showed that rats produced by microinsemination of spermatids or spermatozoa, developed from either fresh or cryopreserved SG cells from immature testis and xeno-transplanted to busulfan-treated mice, were fertile and had a normal imprinting pattern.

Earlier experiments performed on mice suggested that although testicular suspensions containing stem cell SG can be frozen, high survival rate of morphological normal germ cells does not guarantee the functionality of these cells (Frederickx *et al.*, 2004). While lower fertilization was noted after IVF, ICSI with donor spermatozoa, matured in recipients, successfully fertilized the eggs, and fertile offspring were born (Goossens *et al.*, 2003). It is important to study in the future also the functional capacity of the cryopreserved human pre-pubertal SG by *in vitro* maturation or xeno-transplantation experiments.

Different types of testicular cells were detected immuno-histochemically using specific markers. In our experiments, culture and freezing did not influence the antigenicity of the tissue. However, lower numbers of SG were seen in the Cryo II group compared with the fresh and Cryo I groups, probably as a result of cell degeneration. Immuno-histochemical detection of the different cells and tissue compartments gives more detailed information about morphological changes caused by cryopreservation and *in vitro* culture.

In conclusion, the presented protocol for slow programmed freezing with DMSO as a cryoprotectant was efficient at maintaining structural integrity of the SG, SCs and stromal compartment during freezing, thawing and short-term culture. Testicular tissue can be cryopreserved and banked for fertility preservation in pre-pubertal boys before gonadotoxic treatment.

## Acknowledgements

We are thankful to Dr Anna Tolf and Dr Barbara Du Rietz for their helpful discussion in analysing the clinical biopsies. We thank Nicholas Bolton for revising the language. This study was supported by a grant from the Swedish Children's Cancer Foundation and the Karolinska Institutet.

## References

- Bahadur G (2004) Ethics of testicular stem cell medicine. *Hum Reprod* 19,2702–2710.
- Bahadur G, Chatterjee R and Ralph D (2000) Testicular tissue cryopreservation in boys. Ethical and legal issues. *Hum Reprod* 15,1416–1420.
- Bahadur G, Ling KL, Hart R, Ralph D, Wafa R, Ashraf A, Jaman N, Mahmud S and Oyede AW (2002) Semen quality and cryopreservation in adolescent cancer patients. *Hum Reprod* 17,3157–3161.
- Brook PF, Radford JA, Shalet SM, Joyce AD and Gosden RG (2001) Isolation of germ cells from human testicular tissue for low temperature storage and autotransplantation. *Fertil Steril* 75,269–274.
- Coulson C, Kershaw H, Radford J and Larcher V (2001) Semen collection from young cancer patients. *Hum Fertil* 4,131–134.
- Dean W, Bowden L, Aitchison A, Klose J, Moore T, Meneses JJ, Reik W and Feil R (1998) Altered imprinted gene methylation and expression in completely ES cell-derived mouse fetuses: association with aberrant phenotypes. *Development* 125,2273–2282.
- Dobrinski I (2005) Germ cell transplantation. *Semin Reprod Med* 23,257–265.
- Dobrinski I, Avarbock MR and Brinster RL (2000) Germ cell transplantation from large domestic animals into mouse testes. *Mol Reprod Dev* 57,270–279.
- Ehmcke J, Hubner K, Scholer HR and Schlatt S (2006) Spermatogonia: origin, physiology and prospects for conservation and manipulation of the male germ line. *Reprod Fertil Dev* 18,7–12.
- Frederickx V, Michiels A, Goossens E, De Block G, Van Steirteghem AC and Tournaye H (2004) Recovery, survival and functional evaluation by transplantation of frozen-thawed mouse germ cells. *Hum Reprod* 19,948–953.
- Gassei K, Schlatt S and Ehmcke J (2006) De novo morphogenesis of seminiferous tubules from dissociated immature rat testicular cells in xenografts. *J Androl* 27,611–618.
- Geens M, De Block G, Goossens E, Frederickx V, Van Steirteghem A and Tournaye H (2006) Spermatogonial survival after grafting human testicular tissue to immunodeficient mice. *Hum Reprod* 21,390–396.
- Goossens E, Frederickx V, De Block G, Van Steirteghem AC and Tournaye H (2003) Reproductive capacity of sperm obtained after germ cell transplantation in a mouse model. *Hum Reprod* 18,1874–1880.
- Grischenko VI, Keros VA and Bondarenko VA (1999) Effect of human fetotesticular tissue transplantation on functional state of reproductive system at some male infertility forms. *Probl Cryobiol* 4,73–76.
- Grischenko VI, Gerodes AG, Keros VA, Alipova EK, Lutskey LI and Yurchenko GG (2003) Allotransplantation effect of fetoplacental complex cryopreserved tissues on endocrine status of men with oligozoospermia. *Probl Cryobiol* 4,85–89.
- Hreinsson J, Zhang P, Swahn ML, Hultenby K and Hovatta O (2003) Cryopreservation of follicles in ovarian cortical tissue. Comparison of serum and human serum albumin in the cryoprotectant solution. *Hum Reprod* 11,1–9.
- Honaramooz A, Megee S, Rath R and Dobrinski I (2007) Building a testis—formation of functional testis tissue after transplantation of isolated porcine (Sus scrofa) testis cells. *Biol Reprod* 76,43–47.
- Hovatta O (2003) Cryobiology of ovarian and testicular tissue. *Best Pract Res Clin Obstet Gyn* 17,331–342.
- Hovatta O (2001) Cryopreservation of testicular tissue in young cancer patients. *Hum Reprod Update* 7(4),378–383.
- Hovatta O, Foudila T, Sieberg R, Johansson K, von Smitten K and Reima I (1996) Pregnancy resulting from intracytoplasmic injection of spermatozoa from a frozen-thawed testicular biopsy specimen. *Hum Reprod* 11,2472–2473.
- Jahnukainen K, Ehmcke J, Soder O and Schlatt S (2006) Clinical potential and putative risks of fertility preservation in children utilizing gonadal tissue or germline stem cells. *Pediatr Res* 59,40–47.
- Jahnukainen K, Hou M, Petersen C, Setchell B and Soder O (2001) Intratesticular transplantation of testicular cells from leukemic rats causes transmission of leukemia. *Cancer Res* 61,706–710.
- Keros V (1999) Cryopreservation of human fetus testicular tissue and low temperature bank creation for further application in clinical transplantology. *Probl Cryobiol* 3,54–58.
- Keros V, Rosenlund B, Hultenby K, Aghajanova L, Levkov L and Hovatta O (2005) Optimizing cryopreservation of human testicular tissue—comparison of protocols with glycerol, propanediol and dimethyl sulphoxide as cryoprotectants. *Hum Reprod* 20,1676–1687.
- Kliesch S, Behre HM, Jurgens H and Nieschlag E (1996) Cryopreservation of semen from adolescent patients with malignancies. *Med Pediatr Oncol* 26,20–27.
- Kuroda N, Nakayama H, Miyazaki E, Hayashi Y, Toi M, Hiroi M and Enzan H (2004) Distribution and role of CD34-positive stromal cells and myofibroblasts in human normal testicular stroma. *Histol Histopathol* 19,743–751.
- Kvist K, Thorup J, Byskov AG, Hoyer PE, Mollgard K and Yding Andersen C (2006) Cryopreservation of intact testicular tissue from boys with cryptorchidism. *Hum Reprod* 21,484–491.
- Muller J and Skakkebaek NE (1983) Quantification of germ cells and seminiferous tubules by stereological examination of testicles from 50 boys who suffered from sudden death. *Int J Androl* 6,143–156.
- Newton H, Aubard Y, Rutherford A, Sharma V and Gosden R (1996) Low temperature storage and grafting of human ovarian tissue. *Hum Reprod* 11,1487–1491.
- Ogawa T, Ohmura M and Ohbo K (2005) The niche for spermatogonial stem cells in the mammalian testis. *Int J Hematol* 82,381–388.
- Patel RP, Kolon TF, Huff DS, Carr MC, Zderic SA and Canning DA Snyder HM 3rd (2005) Testicular microlithiasis and antisperm antibodies following testicular biopsy in boys with cryptorchidism. *J Urol* 174,2008–2010.
- Robertson JA (2005) Cancer and fertility: ethical and legal challenges. *J Natl Cancer Inst Monogr* 34,104–106.
- Russell LD and Brinster RL (1996) Ultrastructural observations of spermatogenesis following transplantation of rat testis cells into mouse seminiferous tubules. *J Androl* 17,615–627.
- Schlatt S, Kim SS and Gosden R (2002) Spermatogenesis and steroidogenesis in mouse, hamster and monkey testicular tissue after cryopreservation and heterotopic grafting to castrated hosts. *Reproduction* 124,339–346.
- Schlatt S, Honaramooz A, Ehmcke J, Goebell PJ, Rubben H, Dhir R, Dobrinski I and Patrizio P (2006) Limited survival of adult human testicular tissue as ectopic xenograft. *Hum Reprod* 21,384–389.
- Shinohara T, Kato M, Takehashi M, Lee J, Chuma S, Nakatsuji N, Kanatsu-Shinohara M and Hirabayashi M (2006) Rats produced by interspecies spermatogonial transplantation in mice and *in vitro* microinsemination. *Proc Natl Acad Sci U S A* 103,13624–13628.
- Thomson AB, Critchley HO, Kelnar CJ and Wallace WH (2002) Late reproductive sequelae following treatment of childhood cancer and options for fertility preservation. *Best Pract Res Clin Endocrinol Metab* 16,311–334.
- Tournaye H, Goossens E, Verheyen G, Frederickx V, De Block G, Devroey P and Van Steirteghem A (2004) Preserving the reproductive potential of men and boys with cancer: current concepts and future prospects. *Hum Reprod Update* 10,525–532.
- Wallace WH, Anderson RA and Irvine DS (2005) Fertility preservation for young patients with cancer: who is at risk and what can be offered? *Lancet Oncol* 6,209–218.

Submitted on July 4, 2006; resubmitted on October 18, 2006; resubmitted on November 21, 2006; accepted on December 8, 2006